


Sona Imaging Solutions, Inc. online testing and quiz maker - Windows Internet Explorer

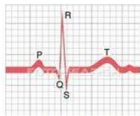
http://www.classmarker.com/embedded_quizzes/ registry exam review

Sona Imaging Solutions, Inc. online testing and q...



Time left: 1 hrs 24 mins 58 secs

Question 8 of 100



The electrical QRS complex represents the onset of what functional cardiac activity?


- a) Isovolumic Relaxation
- b) Ventricular Diastole
- c) Ventricular Systole
- d) Early rapid filling

Next

Sona Imaging Solutions, Inc. online testing and quiz maker - Windows Internet Explorer


http://www.classmarker.com/embedded_quizzes/ registry exam review

Sona Imaging Solutions, Inc. online testing and q...



Time left: 1 hrs 23 mins 19 secs

Question 16 of 100



What is most likely the cause of this patient's condition.


- a) Mitral stenosis
- b) Hypertension
- c) Myocardial infarction
- d) CHF

Next

Sona Imaging Solutions, Inc. online testing and quiz maker - Windows Internet Explorer

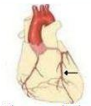
http://www.classmarker.com/embedded_quizzes/ registry exam review

Sona Imaging Solutions, Inc. online testing and q...



Time left: 1 hrs 23 mins 2 secs

Question 18 of 100



The arrow in the image is pointing to which artery?

- a) Circumflex artery
- b) Right coronary artery
- c) Left anterior descending

Next